

## CASE REPORT

### Lamellar Ichthyosis in an Infant

Rajniti Prasad, OP Mishra, U K Singh

**Abstract:** We herewith report a case of lamellar ichthyosis in one year old child who presented with thick dark scaly lesions all over body with ectropion of both eyes and was treated with emollient and topical retinoid therapy. The biopsy of skin showed hyperkeratosis without parakeratosis. The case is being reported for its late presentation to hospital and successful treatment with topical therapy.

**Key words:** Lamellar ichthyosis, Retinoid, Emollient.

**Introduction:** Lamellar ichthyosis is an autosomal recessive disorder that is apparent at birth and is present throughout life. Although disorder is not life threatening, it is quite disfiguring and causes considerable psychological stress to affected parent. The exact incidence this disease in developing countries are not known, however in USA, the incidence is less than 1 case per 3,00,000 individuals<sup>1</sup>. We report first case of lamellar ichthyosis from eastern Uttar Pradesh who presented at the age of one year with ectropion of eyelids and was treated with emollients and topical retinoids.

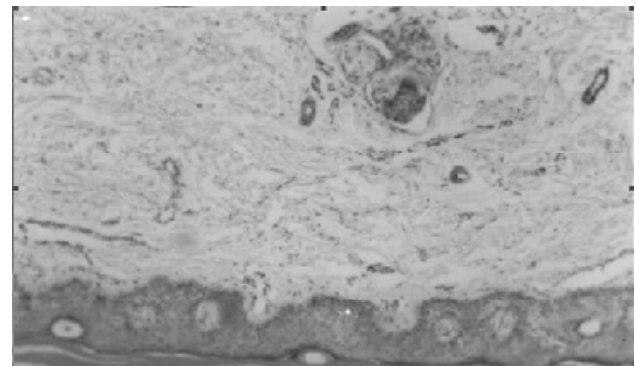
**Case Summary:** One-year-old female child was brought in OPD with asymptomatic progressive lesions all over the body and face since 6 days of life. The patient was the only child born by normal delivery at home. There was no history of similar illness in family. There was a history of consanguinity. On examination, patient had grade II chronic malnutrition (weight = 6.9 kg, height = 62 cm) and multiple plate like large brown, firmly adherent scales on erythematous base, variable in size all over the body, including flexural surfaces, scalp and palms and soles. There were patches of alopecia over scalp. The examination of eyes showed bilateral conjunctivitis and ectropion of eye lids. There was dystrophy of nails of both hands (Fig-1). Systemic examination was normal. The hemogram of patient at admission showed hemoglobin = 13.6 mg/dl, white cell count = 6,800/cumm (54% polymorphs, 42% lymphocytes, 2% monocytes, 2% eosinophils) and platelet of 2,30,000/cumm. Liver and renal function tests were normal. Peripheral smear to rule out lipid storage disease associated was normal. Skin biopsy showed overgrowth of prickle cell layer, thickened

granular, marked hyperkeratosis without parakeratosis, prominent ridges with increased mitoses and perivascular infiltrates (Fig-2). Skeletal survey was normal.

**Figure-1:** Multiple plate like large brown, firmly adherent scales on erythematous base, variable in size all over the body, including flexural surfaces, scalp and palms and soles



**Figure-2:** Skin biopsy showed overgrowth of prickle cell layer, thickened granular, marked hyperkeratosis without parakeratosis, prominent ridges with increased mitoses and perivascular infiltrates



Patient was treated with petrolatum emollient (Vaseline) and topical retinoids with nutritional rehabilitation and asked for follow up in OPD monthly. Child had improved partially at 2 months but few skin lesions and ectropion were present. Local emollient and topical retinoids were continued up to one year. At one year, patient underwent corrective surgery for ectropion. Patient is on regular follow up.

Rajniti Prasad, OP Mishra, U K Singh  
Dept. of Pediatrics, Institute of Medical Sciences,  
BHU, Varanasi

**Corresponding author:**  
E-mail: [rajnitip@yahoo.co.in](mailto:rajnitip@yahoo.co.in)

**Discussion:** Lamellar ichthyosis is an autosomal recessive disorder characterized by onset of ichthyosis at birth, involving the entire body surface. The newborn is usually born encased in a membrane like sheath, the phenotype known as collodion baby which later on sheds within 10-14 days with persistence of scales and variable redness of skin<sup>2</sup>. The scales may be fine and white to thick, dark and plate like as in our case. The scales are arranged in a mosaic pattern resembling fish like. Nail abnormalities include secondary dystrophy with nail fold inflammation, sub-ungual hyperkeratosis and longitudinal and transverse splitting. Scarring alopecia, ectropion, eclabium, bilateral conjunctivitis, small and deformed ear and inflexible digits due to taut skin are other manifestations of lamellar ichthyosis. In neonatal period, there is risk of hypernatremic dehydration and septicemia in such baby<sup>1</sup>.

Patients with lamellar ichthyosis have an accelerated turnover with proliferative hyperkeratosis in contrast to retention hyperkeratosis. The pathogenesis is hypothesized to be due to mutation of gene located on chromosome 14q11 encoding Transglutaminase 1 enzyme, which helps in cross linking of lucrine and involucrine. Lucrine and involucrine serve as the scaffolding in the formation of cell envelope which acts as a physical barrier for epidermis<sup>3</sup>.

The management is aimed at decreasing symptoms and include emollients (petrolatum, coconut oil, alpha hydroxy acetic acid) & keratolytics containing salicylates with propylene glycol and local and systemic retinoids<sup>4</sup>. Salicylates should not be used in children because of risk of systemic intoxication<sup>5</sup>. Topical retinoids decrease the cohesiveness of follicular epithelial cells and thickening of scales and stimulate mitotic activity resulting in an increase in the turnover of follicular cells. It also makes keratinocytes in the sebaceous follicles less adherent and easier to remove. Oral retinoids have been shown to be highly effective as it inhibits sebaceous gland function thus decreases gland size, sebum production and keratinization. Newer therapies that have resulted in clinical improvement are locobase fatty cream, topical N-acetylcysteine which has an antiproliferative effect<sup>6</sup>, Tazarotene (0.05%) a receptor selective retinoids which modulates not only differentiation and proliferation of epithelial tissues but has anti-inflammatory and immunomodulatory properties and caciprotid, a synthetic vitamin D3 derivative. The corrective gene therapy may be a modality of treatment in near future for lamellar ichthyosis<sup>7</sup>. The education of patients for potential heat stress disorder and psychosocial and emotional support is required for the patient and family.

Prenatal diagnosis is still controversial, however amniocentesis and fetal skin biopsy at 22 weeks may aid in early diagnosis of this disorder. In patient with a known gene locus, DNA linkage analysis may be useful, so that pregnancy can be planned accordingly.

#### REFERENCES:

1. Conologue T, Meffert J. Ichthyosis, Lamellar. *emedicine journal* 2002;feb :3(2):. Available from: <http://www.emedicine.com/derm/topic190.htm> accessed August 13, 2005.
2. Verma A, Uttamani N. Collodion baby. *Indian Pediatr* 2001;38;1428.
3. Huber M, Rettler I, Bernasconi K. Mutations of keratinocytes transglutaminase in lamellar ichthyosis. *Sciences* 1995;267:528.
4. Sandler B, Hashimoto K. Collodion baby and lamellar ichthyosis. *J Cutan Pathol* 1998;25(2):116-21.
5. Abdel-Magid EH, El-Awad Ahmed FR. Salicylate intoxication in an infant with ichthyosis transmitted through skin ointment- a case report. *Pediatrics* 1994;94:939-46.
6. Redondo P, Bauza A. Topical N-acetylcysteine for lamellar ichthyosis. *Lancet* 1999;354(9193):1880.
7. Choate KA, Medalie DA, Morgan JR et al. Corrective gene transfer in human skin disorder; lamellar ichthyosis. *Nat Med* 1996;2:1263-1267.
8. Akiyama M, Holbrock K. Analysis of skin derived amniotic fluid cells in 2<sup>nd</sup> trimester, detection of severe genodermatosis expressed in the fetal period. *J Invest Dermatol* 1994;103:674-677.
9. Perry TB, Holbrock K. Prenatal diagnosis of lamellar ichthyosis. *Prenat Diag.* 1987 ; 7:145-155.

**E-published: September 2006**