
LETTER TO EDITOR (VIEWERS CHOICE)

AMNIOTIC BAND SYNDROME

Marwah Ashish, Marwah Poonam

Key words: Amniotic band syndrome, constriction band, digital amputation.

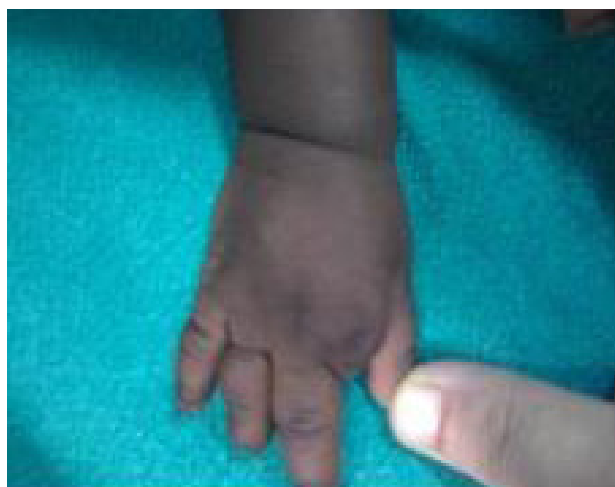
A 1 year old male child presented with constriction ring in left lower limb and digital amputation in right hand. The child was a term (38 weeks) appropriate-for-gestational age (birth weight 2.8kg) born of a non consanguineous marriage by normal vaginal delivery to a primigravida mother (age 23years) at home by a trained birth attendant. The antenatal and immediate postnatal periods were apparently normal. Antenatal care received included iron, folic acid and calcium supplementation, 2 doses of tetanus toxoid, 3 antenatal visits at primary health centre, however, no antenatal ultrasound (USG) was done. No antenatal history of infection, radiation exposure or drug intake was present. On local examination, there was a deep constrictive circumferential groove on left leg just above ankle (figure 1). The groove was confined to skin, subcutaneous tissue and the bones being normal in this area. In right hand, there was complete loss of index finger while ring and little finger showed amputation at level of distal interphalangeal joint (figure 2). The left hand was unaffected. A detailed physical examination revealed a boy of normal somatomental development with a weight of 9.5 kg and length 76 cm. The psychomotor milestones of the child were normal. No other congenital anomalies were detected on a detailed clinical and radiological examination (including skeletal survey, USG viscera and head, echocardiography). The fibrous bands were excised and Z-plasty done was by pediatric orthopedic surgeon of the institute. Subsequent development of leg and foot was normal. For amputated digits, reconstructive surgery was planned.

Amniotic bands are fibrous strands that extend from outer surface of cord into amniotic cavity. Amniotic band sequence is a spectrum of foetal malformations due to these fibrous bands entrapping foetal body parts. It is a rare condition with an

Figure 1. Constrictive circumferential grooves on left leg just above ankle

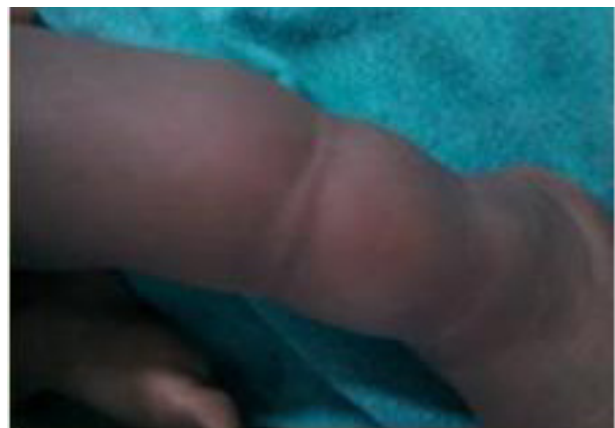

Figure 2. Right hand showing complete loss of index finger and amputation of ring and little finger at distal interphalangeal joint.



incidence of 1:1200 to 1:15000 births. (1) It usually occurs in varying severity ranging from superficial circumferential grooves in skin to digital or whole limb amputation. Other less common defects associated with it are pseudoarthrosis, metatarsus adductus, peripheral nerve palsy, craniofacial abnormalities, spinal dysraphism, porencephaly, hydrancephaly and visceral body wall malformations. (2,3) It has equal incidence among males and females. It is a non genetic entity with no recurrence among siblings or children of affected adult. (3) Numerous theories have been put forward to explain the syndrome, the most accepted one is of premature rupture of membranes with amniotic band formation and disruption of foetal parts due to compression or ischemia from amniotic bands. (4,5) According to Torpin et al, rupture of amnion without rupture of chorion causes transient oligohydramnios due to loss of amniotic fluid through initially permeable chorion. The foetus passes from amniotic to extra-embryonic coelom through defect and comes in contact with sticky mesoderm on chorionic surface of mesoderm. (6) A decidual reaction occurs and amniotic bands (fibrous cords) form which strangle limbs, fingers and other foetal organs. These bands so formed lead to a wide range of birth defects leading to distal atrophy, digital or limb amputation, pseudo-syndactyly, lymphedema, club foot, in addition to severe craniofacial, visceral and trunk deformities. (7,8) The condition is usually idiopathic, however, increased risk has been found in young mothers with low education levels, unplanned pregnancies and non-white, Hispanic races. (9) Maternal trauma, oophorectomy in pregnancy, intrauterine contraceptive device, amniocentesis, have been implicated in some reports. (10-12) Prognosis in such cases is decided by associated anomalies. It is quite good in minor constriction rings and lymphedema while patients with amputation may require reconstructive surgery/prosthesis.

REFERENCES

1. Morovic CG, Berwart F, Varas J. Craniofacial anomalies of amniotic band syndrome in serial clinical cases. *Plast Reconstr Surg* 2004; 113: 1556-1562.
2. Allington NJ, Kumar SJ, Guille JT. Clubfeet associated with congenital constriction bands of ipsilateral lower extremity. *J Pediatr Orthop* 1995; 15: 599-603.
3. Seeds JW, Cefalo RC, Herbert WN. Amniotic band syndrome. *Am J Obstet Gynecol.* 1982; 144: 243-248
4. Kawamura K, Chung KC. Constriction band syndrome. *Hand Clin.* 2009; 25: 257-264.
5. Light TR, Ogden JA. Congenital constriction band syndrome. Pathophysiology and treatment. *Yale J Biol Med.* 1993; 66: 143-155.
6. Torpin R. Fetal malformations caused by amnion rupture during gestation. *Bull Am Coll Nurse Midwives.* 1971; 16: 108-111.
7. Waltes JH Jr, Goss LR, Lazzara AT. Amniotic band syndrome. *J Foot Ankle Surg.* 1998; 37: 325-333.
8. O'Driscoll M, Peckham C, Kerr B. Four limb syndactyly, constriction rings and skin tags; amniotic bands or disorganization-like syndrome. *Clin Dysmorphol.* 2008; 17: 255-258
9. Werler MM, Lovik C, Mitchell AA. Epidemiologic analysis of maternal factors and amniotic band defects. *Birth Defects Res A Clin Mol Teratol.* 2003; 67: 68-72.

From: Department of Pediatrics, Government Medical College and Hospital, Chandigarh.

Address for Correspondence: Dr Ashish Marwah, House no. 1457, Sector 9, HUDA, Ambala city-134003, Haryana, India. Email: ashmar1980@gmail.com

E-published: 1st February 2012 **Art#8**

DOI No. 10.7199/ped.oncall.2012.8
