

Heparan sulphate can be done in urine. Other diagnostic tests are enzyme assay, which helps in carrier detection also. Amniotic fluid or chorionic villus biopsy can also be done for prenatal diagnosis in case of a positive family history {3}.

Authorship details: SK diagnosed the case` PG referred the case for the pediatric consultation and managed the skeletal deformities, RK diagnosed the skeletal deformities.

Conflict of Interest: None

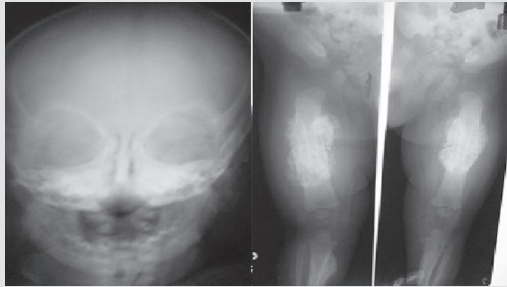
Funding: Nil

References

1. Valstar MJ, Ruijter GJ, van Diggelen OP, Poorthuis BJ, Wijburg FA. Sanfilippo syndrome: A mini-review. *J Inherit Metab Dis.* 2008 Apr 4. {Epub ahead of print}
2. Hochuli M, Wüthrich K, Steinmann B. Two-dimensional NMR spectroscopy of urinary glycosaminoglycans from patients with different mucopolysaccharidoses. *NMR Biomed.* 2003; 16: 224-236.
3. Whiteman P, Young E. The laboratory diagnosis of Sanfilippo disease. *Clin Chim Acta.* 1977; 76: 139-147.

E-published: January 2010

SPOT DIAGNOSIS (IMAGE GALLERY)



Excessive crying and Bone disease

Altaf Naseem, U N Reddy

Department of Pediatrics, Deccan College of Medical Sciences, Hyderabad

Address for Correspondence: Dr. Altaf Naseem, Assistant Professor, Department of Pediatrics, Princess Esra Hospital, Shah ali Banda, Hyderabad - 500 002, Andhra Pradesh, India.
Email ID: docaltaf@rediffmail.com

A 4 month old male child presented with fever, excessive crying and swelling of the face. Plain radiographs were done as shown above.

What is the diagnosis?

Caffey disease or Infantile cortical hyperostosis is a benign, rare, proliferating bone disease affecting infants {1}. Classically, Caffey disease occurs in the first year of life { Less than 5 months}. It is characterized by clinical triad of fever, soft tissue swelling and hyperirritability and a clinching radiograph picture of underlying cortical hyperostosis {2}. Although the etiology of caffey disease remains unclear, many clinical and pathologic features are suggestive of inflammatory process {3}. All races are affected, seen equally in boys and girls {1}. Laboratory investigation may show an elevated ESR, an elevated serum alkaline phosphatase, moderate leukocytosis, thrombocytosis and anemia {4}. Clinical course of caffey disease is highly variable, ranging from self limited to protracted illness. Clinical differential diagnosis includes Osteomyelitis, Parotitis and parotid gland abscess and bone tumors of the affected area. Management is essentially palliative aimed at pain relief but some authors claim a good response to high dose immunoglobulin {5}. Corticosteroids have been used to hasten bone remodeling and Indomethacin has been used to control flare ups.

Contributors credits: AN collected the data and drafted the article and revised the manuscript for important intellectual content. He will act as guarantor of the study. UNR helped in manuscript writing. The final manuscript was approved by all authors

Source of Funding: nil

Competing interests: nil

References

1. Caffey J. Infantile Cortical Hyperostosis. *J Pediatr.* 1946; 29: 541-549
2. Carey BE. Neonatal cortical hyperostosis. *Neonatal Netw.* 2000; 19: 55-57
3. Pazzaglia UE, Byers PD, Beluffi G, et al. Pathology of infantile cortical hyperostosis {Caffey`s disease}. Report of a case. *J Bone Joint Surg Am.* 1985; 67: 1417-1426
4. Kamoun-Goldrat A, le Merrer M. Infantile cortical hyperostosis {Caffey disease}: a review. *J Oral Maxillofac Surg.* 2008; 66: 2145-2150
5. Berthier M, Bonneau D, Huret JL. Caffey disease responding to high-dose immunoglobulin. *Eur J Pediatr.* 1988; 147: 443-444

E-published: February 2010