

IMAGES IN CLINICAL PRACTICE

ONE TOO MANY BONES

Margarida Almendra¹, Vera Brites¹, Pedro António Jordão², João Falcão Estrada¹.

¹Pediatric Intensive Care Unit, Hospital Dona Estefânia, Centro Hospitalar Universitário Lisboa Central, EPE,

²Orthopedics Department, Hospital Dona Estefânia, Centro Hospitalar Universitário Lisboa Central, EPE.

KEYWORDS

Sprengel deformity, Klippel-Feil Syndrome, shoulder asymmetry, omovertebral bone.

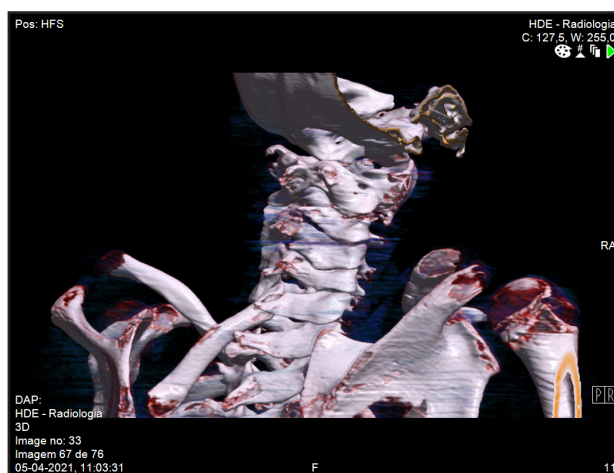
ARTICLE HISTORY

Received 13 November 2021

Accepted 20 December 2021

A 6-year-old girl with a personal history of global development delay, epilepsy and cardiopathy was referred to the Orthopaedic Department due to shoulder asymmetry. She complained of functional limitation in daily activities, no pain registered and recently, frequent falls with lower extremity weakness. On physical examination, the left shoulder and scapula were at a higher level and limited abduction was noted on the left shoulder. Spine x-ray revealed toraco-lombar scoliosis. Cervical computed tomography (CT) and magnetic resonance with three-dimensional reconstruction revealed multiple vertebral malformations and an omovertebral bone that runs from the superior internal border of the scapula to the posterior arch of C6 (Figure 1). She required a surgery where an 8 cm omovertebral bone exeresis was performed, without complications. On follow-up, neurologic symptoms resolved and the patient described no pain and improved shoulder abduction mobility and cosmetics.

Figure 1. 3D Cervical CT scan.



What is your diagnosis?

Sprengel deformity is a congenital elevation of the scapula.^{1,2,3,4,5} Although rare, it is the most common congenital malformation of the shoulder.^{1,3,4,5} It is unilateral

in approximately 90% of the cases³ with a predilection for left side^{1,4} and it has a male predominance (3:1).^{1,3} It occurs as a result of failure of the scapula to descend to its correct position during intrauterine development¹⁻⁵ being characterized by abnormal position of scapula and dysplasia with muscular atrophy^{1,3}; its cause is still unknown.^{3,4}

Even though the deformity appears randomly, familial cases have been reported.^{1,4}

It can present as a single entity or associated with other syndromes, the most common being Klippel-Feil Syndrome^{1,3,5} – an anomaly characterized by congenital fusion of a variable number of cervical vertebrae – present in about 19-27% of patients with Sprengel's deformity.^{1,3} These associated vertebrae malformations can be explained by the common embryonic origin of the scapula and cervical spine.³

In its most severe form (in 25-50% of the cases), there is an omovertebral connection where the scapula is connected to the cervical spine by a congenitally anomalous ossification (fibrous, cartilaginous and/or osseous connection), leading to a stiff and elevated scapula with limited range of motion.^{2,3,5}

Other linked bony and spinal cord abnormalities include spina bifida, congenital scoliosis and diastematomyelia.^{1,2} In this case report, multiple vertebral anomalies suggestive of Klippel-Feil Syndrome was found as well as left hemi-medular myelomalacia in C4-C5. Anteroposterior X-ray imaging can confirm the diagnosis. However, computed tomography and magnetic resonance scans with three-dimensional reconstruction are nowadays used to detail the degree of the deformity, evaluate the omovertebral connection, diagnose concomitant abnormalities and plan appropriate treatment.^{3,4,5}

Treatment can be conservative or surgical. Conservative treatment is reserved for patients with minor deformity and no functional limitation in daily activities.^{1,3} Surgery is considered for patients with severe limitation of scapular function, neck pain or to improve cosmetic.^{1,3,5} It is usually performed between the ages of 3 and 8 years old.^{1,3,5}

In this case report, due to the intracanal omovertebral bone localization, local myelomalacia and left hemiparesis, she needed surgical correction. An 8 cm omovertebral bone exeresis was performed, without complications. On follow-up, neurologic symptoms resolved and the patient described no pain and improved shoulder abduction mobility and cosmetics.

Address for Correspondance: Maria Margarida dos Reis Gomes Almendra, Hospital Dona Estefânia, Rua Jacinta Marto, 1169-045 Lisbon, Portugal

Email: margaridaalmendra@gmail.com

©2023 Pediatric Oncall

Compliance with Ethical Standards

Funding None

Conflict of Interest None

References:

1. Silva I et al. Misaligned shoulders. *Nascer e Crescer - Birth and Growth Medical Journal* 2021;30(2): 125-127. doi:10.25753/BirthGrowthMJ.v30.i2.19122
2. Brett-Fleegler M. Approach to neck stiffness in children. In *Uptodate*. Last updated: Jun 30, 2021. Access on 15/10/2021
3. Araújo F. Doença de Sprengel - A Case Report. Trabalho final mestrado integrado em medicina. Faculdade de Medicina de Lisboa. Julho 2018
4. Bindoudi A et al. The Rare Sprengel Deformity: Our Experience with Three Cases. *J Clin Imaging Sci*. 2014;4:55
5. Trajcevska, E., Bickle, I. Sprengel deformity. Reference article, *Radiopaedia.org*. (accessed on 14 Oct 2021) <https://radiopaedia.org/articles/20833>