

CASE REPORTS

BREATHLESSNESS IN A CHILD EXPOSED TO COVID-19

Meghana Phadke, Vishwajeet Sonu, N R Harish.

Department of Pediatrics, Metro Heart and Super Specialty Hospital, Faridabad, Haryana, India.

ABSTRACT

A 4-year-old boy suffering from celiac disease on gluten free diet and in close contact with a COVID-19 patient for 2 weeks presented with fever 101 degree F, diarrhea and breathlessness with hypoxia. COVID-19 RT PCR and inflammatory markers were negative. There was pneumothorax on right side with lacy bullous pattern on chest x-ray. CT chest showed bilateral cystic lung disease. Lung biopsy showed moderately dense diffuse nodular infiltrates of oval to medium sized Langerhans cells. It also showed CD1a and S100 positivity on immunohistochemistry confirming Langerhans Cell Histiocytosis (LCH). There was no bone, skin, liver, or lymph node affected suggestive of isolated pulmonary LCH.

ARTICLE HISTORY

Received 13 July 2021

Accepted 20 August 2021

KEYWORDS

Isolated PLCH, Bilateral cystic lung disease, breathlessness, desaturation

Introduction

Pulmonary Langerhans Cell Histiocytosis (PLCH) with few or more systemic involvement is common in adults with smoking as strong association whereas in children 1 to 10 per million is the estimated incidence of all Langerhans Cell Histiocytosis (LCH) cases under 15 years of age.¹ It has slight male preponderance (1.2 to 1.4:1).¹ Isolated pulmonary LCH is rare and exact incidence is not available. Breathlessness is a feature of both COVID-19 infection and PLCH. However, ground glass appearance is a feature of COVID-19 infection and cystic lung disease is a feature of PLCH.² We present a confusing case of a 4-year-old boy with exposure to COVID-19 who developed breathlessness but was subsequently diagnosed to have PLCH.

Case Report

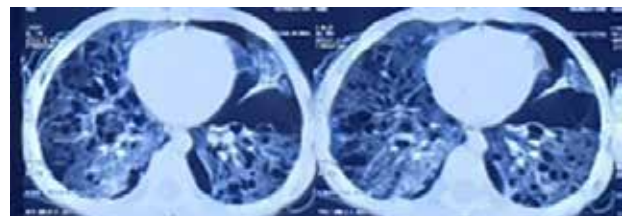
A 4 year old boy suffering from celiac disease on gluten free diet and in close contact with a COVID-19 patient for 2 weeks presented with fever 101 degree F, diarrhea and breathlessness with hypoxia for 5 days. On examination child was 13 kg and had respiratory rate of 45 with room air oxygen saturation of 88%, pulse rate of 110/min, axillary temperature of 101.0F and decreased air entry on right side of chest. Rest of the systemic examination was normal. Nasopharyngeal swab for Covid-19 RT PCR done 10 days ago as well as on admission was negative. Hemoglobin was 10.2 gm%, white cell count was 16,370/cumm with platelet count of 725,000/cumm and ESR of 24 mm at end of 1 hour. Chest x-ray was suggestive of right sided pneumothorax with pushed effect on heart while electrocardiogram (ECG) was normal. Chest tube drainage was done for pneumothorax and patient was started on oxygen, intravenous (IV) fluids and IV antibiotics (amoxicillin-clavulanate and amikacin).

After chest tube drainage, a repeat chest X-ray showed hyperinflated right lung with lacy bullous pattern (figure 1). Mantoux test and gastric aspirate for acid fast bacilli were negative. CT chest revealed diffuse numerous

Figure 1. Chest X-ray showed hyperinflated right lung with right sided pneumothorax and right chest tube with bilateral lacy bullous pattern

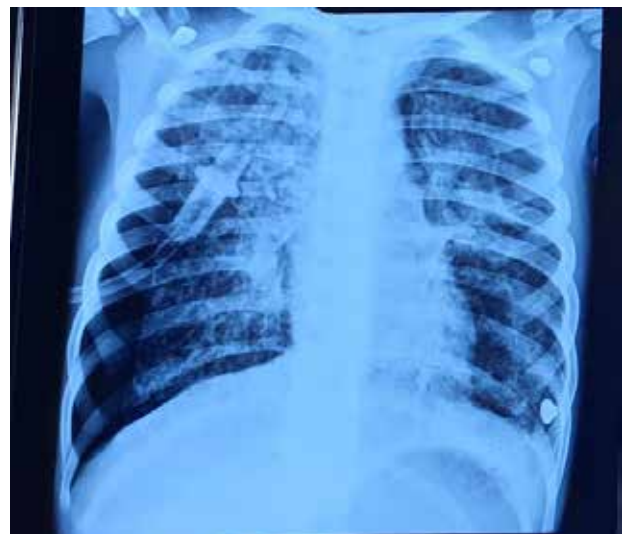

Figure 2. CT chest revealed diffuse numerous cysts of variable size, shape and wall thickness in both lung fields with few tiny solid nodules in right lower lobe with generalized ground glass haziness with mild right sided pneumothorax



Address for Correspondance: Dr Meghana Phadke, OPD no 2001, new OPD wing, Metro Heart and Super Specialty Institute, Sector 16A, Faridabad 121002, Haryana, India.

Email: meghana.sp@gmail.com

©2021 Pediatric Oncall

moderately dense diffuse nodular infiltrates of oval to medium sized Langerhans cells. It also showed CD1a and S100 positivity on immunohistochemistry confirming LCH. Hence child was started on IV vincristine (1.5 mg/m²) and oral prednisolone (40 mg/m²). Bone marrow was normocellular with mildly suppressed erythropoiesis and no abnormal aggregates of lymphoid or histiocyte series. With the diagnosis of isolated PLCH, child was referred to pediatric oncologist and pulmonologist.

Discussion

LCH is clonal proliferative disorder of mononuclear phagocyte system, commonly called histiocytosis.¹ These are immature histiocytes which abnormally accumulate to different tissues and organs of the body. Etiopathogenesis is mysterious. Apart from genetic predisposition, role of viral infections acting as stimuli and abnormalities in the interleukins (IL 1 alpha, IL 10), lymphocytes is possible.¹ Multisystem involvement is common but not much data is available as to what initiates isolated pulmonary involvement while other organs remain normal. In adults it's almost always smoking which is contributing factor.³ PLCH generally, presents as recurrent dry cough, chest pain, shortness of breath, fast breathing. Among constitutional symptoms weight loss is common and fever 101 degree F being rare. Clinically recurrent pneumothorax is common presentation in these children.^{3,4} In multisystem disease lung symptoms are often last ones to appear while extra pulmonary manifestations dominate presentation.

On chest x-ray findings of cystic pattern should raise suspicion. In early disease reticulonodular pattern with interstitial infiltrates are seen. So, HRCT is diagnostic with almost always bilateral lung involvement with often large bullae and hardly present lung parenchymal tissue at times. Most commonly upper and middle lobe involvement is seen with costophrenic angle involved as well.⁴ Lung biopsy or bronchoalveolar lavage

showing CD1a (definitive diagnosis) and S100 positivity confirms presence of LCH. Pathologically inflammatory infiltrates with histiocytes can be seen. Presence and demonstration of Birbeck granules is gold standard.⁴

Chemotherapy is mainstay with vincristine and prednisolone being basic therapy.^{4,5} Cladribine and cytarabine have also been used.^{4,5} Hematopoietic stem cell transplant has also been considered but still is under research. Specific management for pulmonary point of view is for recurrent pneumothorax. Pleurodesis is sometimes done for same.^{4,5} Biological agents targeting MAPK pathway are under research like Dabrafenib/Trametinib. Vaccination with influenza and pneumonia coverage is important aspect.^{4,5} Overall prognosis of isolated pulmonary LCH is better than multisystem. There is no exact data for survival rate in isolated PLCH.

Compliance with Ethical Standards

Funding: None

Conflict of Interest: None

References:

1. Jezierska M, Stefanowicz J, Romanowicz G, Kosiak W, Lange M. Langerhans cell histiocytosis in children - a disease with many faces. Recent advances in pathogenesis, diagnostic examinations and treatment. *Postepy Dermatol Alergol.* 2018;35:6-17.
2. Kaur S, Mishra D, Juneja M. Diffuse cystic lung disease in a child. *Lung India.* 2015;32:186-187.
3. Patra A, Bhattacharyay S, Maji A, Mandal A. Pulmonary Langerhans cell histiocytosis causing spontaneous bilateral pneumothorax in a child. *Egypt J Intern Med.* 2015;27:38.
4. Barclay M, Devaney R, Bhatt JM. Paediatric pulmonary Langerhans cell histiocytosis. *Breathe (Sheff).* 2020;16:200003.
5. Kobayashi M, Tojo A. Langerhans cell histiocytosis in adults: Advances in pathophysiology and treatment. *Cancer Sci.* 2018;109:3707-3713.