

## IMAGES IN CLINICAL PRACTICE

### DYSPHAGIA IN AN ADOLESCENT GIRL

Jiaxuan Siew, Zi Xean Khoo

Department of Pediatrics, KK Women's and Children's Hospital, Singapore

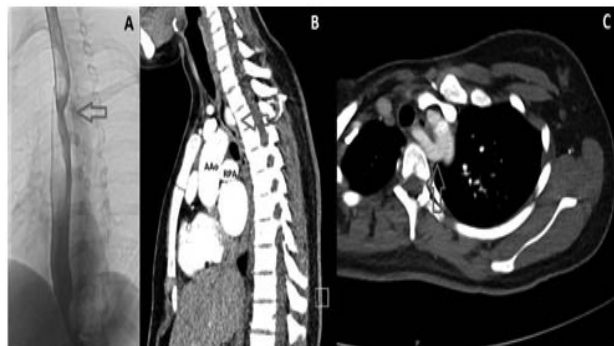
#### ARTICLE HISTORY

Received 25 July 2018

Accepted 15 September 2018

A 17-year-old girl with a history of autoimmune hemolytic anemia (AIHA) presented with acute chest pain and dysphagia. There was no giddiness, syncope or effort intolerance. On examination, she was pale, mildly jaundiced and had splenomegaly. Investigations revealed anemia with reticulocytosis, unconjugated hyperbilirubinemia and positive direct Coomb's test consistent with a relapse of AIHA. Cardiac enzymes, chest X-Ray, and electrocardiogram were normal. She was started on prednisolone and her anemia improved. A barium swallow was performed when her symptoms persisted, which revealed posterior indentation of the proximal esophagus at the level of T3-4 (Figure 1A). Computed tomographic (CT) thorax is depicted in Figure 1B and 1C. Esophagogastroduodenoscopy showed mild gastritis but confirmed the area of extrinsic compression with proximal dilatation of the esophagus.

**Figure 1:** Arrows indicate posterior indentation of the proximal esophagus seen on barium swallow fluoroscopy (A) and CT thorax (B and C).



*What is the diagnosis?*

#### Discussion

CT thorax showed an aberrant right subclavian artery (ARSA) originating as the last branch of the aortic arch, coursing posteriorly indenting the posterior esophagus, consistent with dysphagia lusoria. The patient was referred to cardiothoracic service but as her symptoms were mild, she was treated conservatively with proton pump inhibitors and lifestyle modification.

**CONTACT** Jiaxuan Siew

**Email:** [siew.jia.xuan@singhealth.com.sg](mailto:siew.jia.xuan@singhealth.com.sg)

**Address for Correspondence:** Department of Pediatrics, KK Women's and Children's Hospital, 100 Bukit Timah Road, Singapore, SG 229899.

©2019 Pediatric Oncall

Dysphagia lusoria describes swallowing difficulties secondary to esophageal compression by an ARSA. ARSA is the most common anomaly of the aortic arch with an incidence ranging from 0.5% to 1.8%. (1-3) While majority remain asymptomatic, symptoms may affect the very young and adults if compression is significant. Children typically present with respiratory symptoms while adult patients present with dysphagia and chest pain. Infrequently, dysphagia has been reported in pediatric patients. (4,5) A barium swallow is suggestive but CT or MRI angiography are best for diagnosis. (3) Surgical management is reserved for severe cases.

#### Contributors

JX Siew prepared the manuscript. ZX Khoo reviewed and edited the manuscript and is the primary physician of the patient.

#### Acknowledgments

The authors are grateful to Benjamin Wan HE for his assistance in summarizing the case.

#### Compliance with Ethical Standards

**Funding:** None

**Conflict of Interest:** None

#### References :

1. Richardson JV, Doty DB, Rossi NP, Ehrenhaft JL. Operation for aortic arch anomalies. *Ann Thorac Surg* 1981; 31: 426-32.
2. Carrizo GJ, Marjani MA. Dysphagia lusoria caused by an aberrant right subclavian artery. *Tex Heart Inst J* 2004;31:168-171
3. Abraham V, Mathew A, Cherian V, Chandran S, Mathew G. Aberrant subclavian artery: anatomical curiosity or clinical entity," *International J Surg*. 2009; 7:106-109, 2009
4. Erami C, Charaf-Eddine A, Aggarwal A, Rivard AL, Giles HW, Nowicki MJ. Dysphagia lusoria in an infant. *J Pediatr*. 2013;162:1289-90
5. Barone C, Carucci NS, Romano C. A Rare Case of Esophageal Dysphagia in Children: Aberrant Right Subclavian Artery. *Case Rep Pediatr*. 2016; Article ID 2539374